



Automation, Surgery Support and Intuitive 3D visualization  
to optimize workflow in image guided therapy SysTems

## DELIVERABLE D1.2

End user goals and requirements



Project number:	ITEA 20044
Document version no.:	v0.1
Edited by:	Serdar Sultanoğlu
Date:	13.11.2022

### ITEA Roadmap challenge:

Smart Health

This document and the information contained are the property of the ASSIST Consortium and shall not be copied in any form or disclosed to any party outside the Consortium without the written permission of the Project Coordination Committee, as regulated by the ASSIST Consortium Agreement and the ITEA4 Articles of Association and Internal Regulations.



## HISTORY

Document version #	Date	Remarks
V0.1	12.07.2022	Starting version, template
V0.2	15.10.2022	Integrated Version Compilation of first input by partners: <ul style="list-style-type: none"><li>• Tufan Dogan</li><li>• Rickard Cronholm</li><li>• William van der Sterren</li><li>• Jouke Dijkstra</li><li>• Serdar Sultanoglu</li></ul>
V0.3	28.10.2022	Reviewed Version
V1.0	13.11.2022	Final version

### Deliverable review procedure:

- **2 weeks before due date:** deliverable owner sends deliverable –approved by WP leader– to Project Manager
- **Upfront** PM assigns a co-reviewer from the PMT group to cross check the deliverable
- **1 week before due date:** co-reviewer provides input to deliverable owner
- **Due date:** deliverable owner sends the final version of the deliverable to PM and co-reviewer



## TABLE OF CONTENTS

<b>1</b>	<b>INTRODUCTION.....</b>	<b>4</b>
<b>2</b>	<b>CLINICAL DISEASE AREAS.....</b>	<b>5</b>
<b>2.1</b>	<b>Intracranial haemorrhage.....</b>	<b>5</b>
2.1.1	Introduction.....	5
2.1.2	Clinical state of the art .....	5
2.1.3	Workflow inefficiencies and bottlenecks.....	8
2.1.4	End user goals and requirements .....	9
<b>2.2</b>	<b>Brain tumours.....</b>	<b>10</b>
2.2.1	Introduction.....	10
2.2.2	Clinical state of the art .....	11
2.2.2.1	Surgery .....	11
2.2.2.2	Radiotherapy.....	12
2.2.2.3	Chemotherapy .....	12
2.2.3	Workflow inefficiencies and bottlenecks.....	13
2.2.4	End user goals and requirements .....	13
<b>2.3</b>	<b>Lung Cancer.....</b>	<b>14</b>
2.3.1	Introduction.....	14
2.3.2	Clinical state of the art .....	15
2.3.3	Workflow inefficiencies and bottlenecks.....	17
2.3.4	End user goals and requirements .....	19
<b>2.4</b>	<b>Hepato Pancreato Biliary oncology (HPB).....</b>	<b>19</b>
2.4.1	Introduction.....	19
2.4.2	Clinical state of the art .....	21
2.4.3	Workflow inefficiencies and bottlenecks.....	24
2.4.4	End user goals and requirements .....	25
<b>2.5</b>	<b>Prostate enlargement.....</b>	<b>26</b>
2.5.1	Introduction.....	26
2.5.2	Clinical state of the art .....	27
2.5.3	Workflow inefficiencies and bottlenecks.....	29
2.5.4	End user goals and requirements .....	30
<b>3</b>	<b>CONCLUSIONS.....</b>	<b>32</b>
<b>4</b>	<b>REFERENCES.....</b>	<b>33</b>



## 1 Introduction

The main objective of this deliverable is to define the requirements of the clinical use cases defined in D1.1 Use Case Description Report which are intracranial haemorrhage, brain tumours, lung diseases, liver and hepato pancreato biliary (HPB) oncology, and prostate enlargement.

This document focuses on the clinical aspects of the use cases from end user perspective and leaves the definition of technical requirements to the technical work packages, WP2, WP3, WP4 and WP5.



## 2 Clinical disease areas

### 2.1 Intracranial haemorrhage

Owner: Innova – Tufan Dogan

#### 2.1.1 Introduction

Intracranial hemorrhage refers to any bleeding within the intracranial vault, including the brain parenchyma and surrounding meningeal spaces (Caceres, 2012). Acute intracranial hemorrhage (ICH) is a potentially life-threatening condition that requires fast and accurate detection because of its frequently rapid progression during the first several hours.

ICH could be caused by various reasons ranging from trauma, vascular disease to congenital development (Ye, 2019). Hypertension and Cerebral amyloid angiopathy are the most common causes of hemorrhagic stroke. Cigarette smoking and moderate or heavy alcohol consumption, diabetes mellitus, chronic liver disease, decreased low-density lipoprotein cholesterol and low triglycerides are other important risk factors (Unnithan AKA, 2022). Severe headache, loss of consciousness, vomiting, neck stiffness increases in blood pressure are neurological symptoms often associated with intracranial hemorrhage. (Burduja, 2020) (Unnithan AKA, 2022)

The age-standardized incidence of stroke in Europe ranged from 95 to 290/100,000 per year and absolute number of stroke cases is expected to reach 1.5 million per year in 2025 cases (Béjot, 2016). Haemorrhagic stroke contributes to 10% to 20% of strokes annually (Unnithan AKA, 2022). However, it is deadlier, with a reported case fatality ratio of 24–37% at 7 days and 40–59% at 30 days (Qdaisat, 2022)

The costs of hospitalization for stroke are also high and differed substantially by types of stroke. Due to frequent imaging and surgical intervention, patients admitted with intracranial haemorrhage have the potential to account for significant costs. Fernando et al (2018) found that the mean total cost for intracranial patients was C\$75,869 and the mean cost per day for intracranial hemorrhage patients was C\$3,994. (Fernando, 2018) The estimated US national cost was \$12.55 billion for intracerebral haemorrhage ICH-related hospitalization in 2011–2012 and mean cost per person for hospitalization is \$24,077 and monthly 3-year homecare cost is \$14,487 in the United States (Yousufuddin, 2020).

#### 2.1.2 Clinical state of the art

Intracranial hemorrhage (ICH), a subtype of stroke, can be classified into five subtypes according to bleeding location: Intraventricular (IVH), Intraparenchymal (IPH), Subarachnoid (SAH), Epidural (EDH) and Subdural (SDH). The ICH that occurs within the brain issue is called UnHemorrhage (Figure 1). Although ICH are less frequent than ischemic stroke, it presents higher mortality rate. The degrees of severity and interventions vary with bleeding types (Ye, 2019).

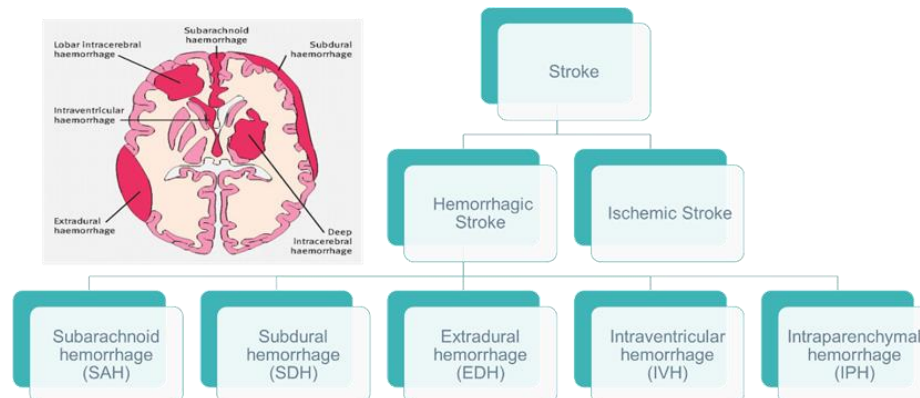


Figure 1 Sub-types of stroke and haemorrhagic stroke

Emergency treatment differs for hemorrhagic and ischemic strokes. In ischemic strokes, emergency IV medication and emergency endovascular procedures are options to restore blood flow to the brain quickly. Carotid endarterectomy, angioplasty and stents are other procedures to decrease risk of having another stroke. On the other hand, emergency treatment of hemorrhagic stroke focuses on controlling the bleeding and reducing pressure in the brain. Emergency measures, surgery, surgical clipping, coiling, surgical arteriovenous malformation removal and stereotactic radiosurgery are treatment options for hemorrhagic strokes (Clinic).

Classification of ICH and distinguishing it from ischemic stroke is critical due to prompt appropriate treatment and mitigate neurological deficit, and mortality. In ischemic strokes, therapy with drugs that can break up a clot has to be given within 4.5 hours from when symptoms first started if given intravenously. Intravenous tissue-type plasminogen activator (IV-tPA) is the gold standard treatment for ischemic stroke. It improves outcomes in ischemic stroke but is associated with certain risks such as potential bleeding in the brain. Differentiating extradural hemorrhage from subdural (SDH) hemorrhage in the head is also important. While extradural hemorrhage is treated with expedient evacuation via a craniotomy, SDH has various management strategies depending on the size, location and extent of mass effect.

Non-contrast Computed Tomography scan is usually the first imaging method used to assess patients with suspected ICH and distinguish ICH from ischemic stroke as it can be performed fast and has high sensitivity for hemorrhage. Hemorrhage and its subtypes can be recognized on non-contrast CT since blood has slightly higher density (Figure 2). CT scans generate a sequence of images using X-ray beams. Depending on the amount of tissue X-ray absorbency, brain tissues are captured with different intensities. CT scans are displayed using a windowing method. Different features of the brain tissues can be displayed in the grayscale image by selecting different window parameters. In the CT scan images, the ICH regions appear as hyperdense regions with a relatively undefined structure (Hssayeni, 2020). However, there are difficulties in using CT scan to detect hemorrhages due to their similar appearance with the parenchyma and complexity in distinguishing mass effect and edema (Mirza, 2017). Even highly trained experts may miss subtle life-threatening findings and many hospitals do not have trained neuro-radiologists, especially at night and on weekends.

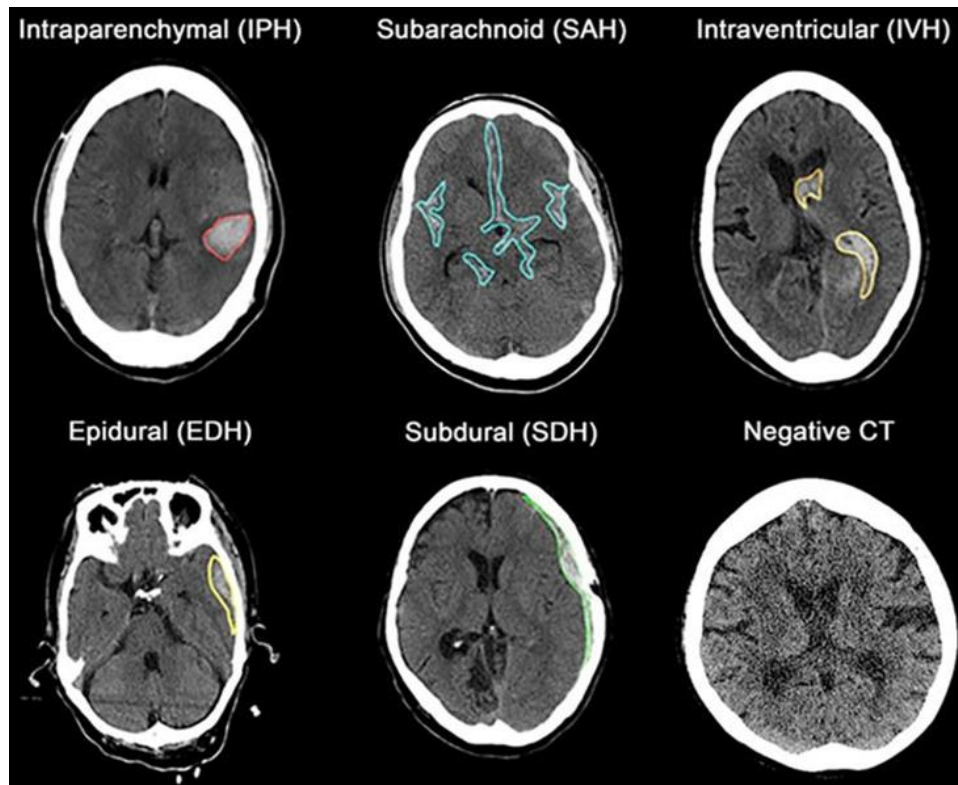


Figure 2 Non-contrast Computed Tomography scans for ICH sub-types. Note. Reprinted from (Kim, 2021)

Although acute stroke is one of the most common causes of disability worldwide and numbers are projected to increase, timely access to modern treatments is most often restricted to urban populations, particularly those living in rural and remote areas. Figure 3 illustrates the workflow for a stroke patient being transferred from a rural facility to a regional hospital center. At this workflow, interpretation of CT images has highest priority.



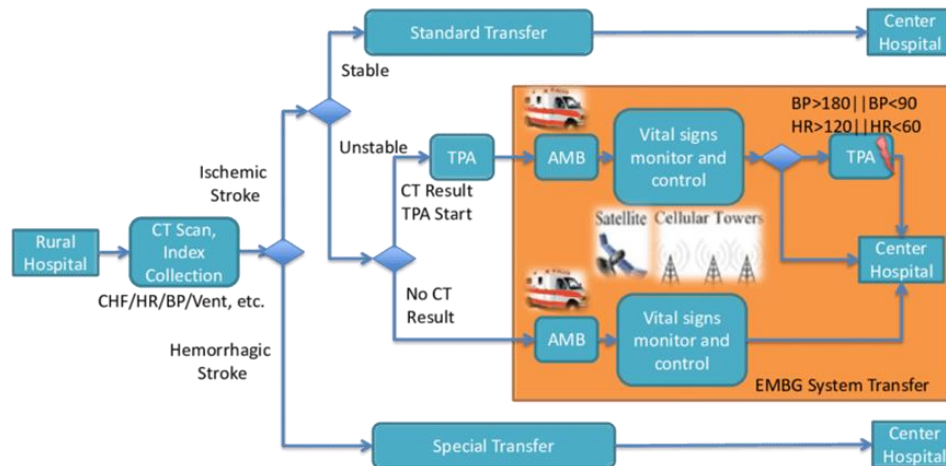


Figure 3 Clinical workflow for stroke patient care from a rural hospital to a regional center hospital. Note. Reprinted from “A Mobile Geo-Communication Dataset for Physiology-Aware DASH in Rural Ambulance Transport. Proceedings of the 8th ACM on Multimedia Systems Conference” (Hosseini, 2017)

### 2.1.3 Workflow inefficiencies and bottlenecks

The main challenges in ICU diagnosis and treatment are shown in Table 1. A system that identifies intracranial hemorrhage with high accuracy comparable to experts has a great potential to help reduce mortality rates and costs. The system that allows the medical staff in the emergency department in rural area for triaging an acute stroke patient who may be eligible for tissue-type plasminogen activator can not only improve your chances of survival but also may reduce complication. A tool for expeditious and accurate diagnosis of ICHs may facilitate a prompt therapeutic response and ultimately improved outcomes. Recent advances in deep convolutional neural networks have showed that the method has a great potential in automating ICH detection and segmentation and can assist junior radiology trainees when experts are not available. The automated triage system for accurate ICH detection is also desirable to reduce the rate of misdiagnosis.

Table 1: (Burduja, 2020) (Patel, 2019) (Hssayeni, 2020) (Unnithan AKA, 2022) (Ye, 2019)

Category	Challenge
Interpretation difficulty of non-contrast CT images	Image noise, artefacts and cerebral parenchyma with similar appearance and density make segmentation of ICH challenging
	Differentiating extradural (EDH) from subdural (SDH) hemorrhage in the head can be challenging as SDHs are more common and there are a few distinguishing features which are usually reliable
	Irregularity of the hematoma and different stages of clot formation may further contribute to obscure hemorrhage boundaries and internal heterogeneity
	Gray scale images are limited by low signal-to-noise, poor contrast, and a high incidence of image artifacts. A unique challenge is to identify tiny subtle abnormalities in a large 3D volume with near-perfect sensitivity





Lack of resources	<p>In most clinical centers, initial interpretations of head CT is usually provided by junior radiologists, radiology trainees, or emergency physicians and initial interpretations will be reviewed later by senior or more-experienced radiologists. Several studies have confirmed that discrepancies exist between the initial and final interpretations and some misinterpretations might even cause clinical consequences</p>
	<p>Diagnosis process relies on the availability of a subspecialty-trained neuroradiologist, and as a result, could be time inefficient and even inaccurate, especially in remote areas where specialized care is scarce.</p>
Time-consuming decision-making process	<p>The urgency of the procedure, a complex and time-consuming decision-making process, an insufficient level of experience in the case of novice radiologists, and the fact that most emergencies occur at night time</p>

#### 2.1.4 End user goals and requirements

- High-performance system for the detection and classification of ICH using non-contrast Computed Tomography images to reduce the rate of misdiagnosis
- Achievement of a performance similar to that of expert radiologists (sensitivity of 98% and specificity of 95%)
- High speed and accurate detection of ICH and its five subtypes (IVH, IPH, SAH, EDH and SDH) to assist health professionals for more prompt and better decision-making regarding treatment planning
- Differentiating ICH subtypes with high performance, extradural hemorrhage (EDH) and subdural hemorrhage (SDH) in particular.
- Handling CT scans with different slice thicknesses, thinner slices provide better contrast and finer image details but causes higher radiation dose to the patients
- Accurate results on both thin and thick slice head CT scans for a reliable tool in real clinical environments
- Visualizing the model decision and increasing interpretability is especially helpful for users with insufficient experience with ICH, especially in remote areas where specialized care is scarce
- Support for end user Explainable AI, which is key to safe, ethical, fair, and trust-able use of system and its deployment in the real world
- Compliance to HL7 and DICOM standards and requirements for easy integration to hospital systems
- Support for cloud and on-premise offerings



## 2.2 Brain tumours

Owner: Spectronic/LiU - Rickard Cronholm, Spectronic

### 2.2.1 Introduction

A brain tumor is caused by abnormal cells that form in the brain and is an uncontrolled growth of cells from brain components (primary tumors) or from tumor cells in other areas of the body (metastases). There are hundreds of different types of primary brain tumors with different prognosis and treatment. All types of brain tumors can cause symptoms, which vary depending on which part of the brain is affected. These include headaches, epileptic seizures, vision problems, vomiting, and altered states of consciousness. More specific problems include difficulties with walking, speaking or sensory experiences.

Aside from exposure to vinyl chloride or ionizing radiation, there are no known environmental factors associated with brain tumors. Mutations and deletions of tumor suppressor genes, such as P53, are thought to be the cause of some forms of brain tumor. Inherited conditions, such as Von Hippel–Lindau disease, tuberous sclerosis, multiple endocrine neoplasia, and neurofibromatosis type 2 carry a high risk for the development of brain tumors.

The annual global age-standardized incidence of primary malignant brain tumors is ~3.7 per 100,000 for males and 2.6 per 100,000 for females. Rates appear to be higher more developed countries (males, 5.8 and females, 4.1 per 100,000) than in less developed countries (males 3.0 and females 2.1 per 100,000). In the United States in 2015, approximately 166,039 people were living with brain or other central nervous system tumors. Over 2018, it was projected that there would be 23,880 new cases of brain tumors and 16,830 deaths in 2018 as a result, accounting for 1.4 percent of all cancers and 2.8 percent of all cancer deaths.

There are differences in the incidences of brain cancer in men and women, regardless of the age of those affected. Men are over represented in the incidence of malignant tumors, while women have a higher incidence for non-malignant tumors. There is no consensus within the research community for this disparity.

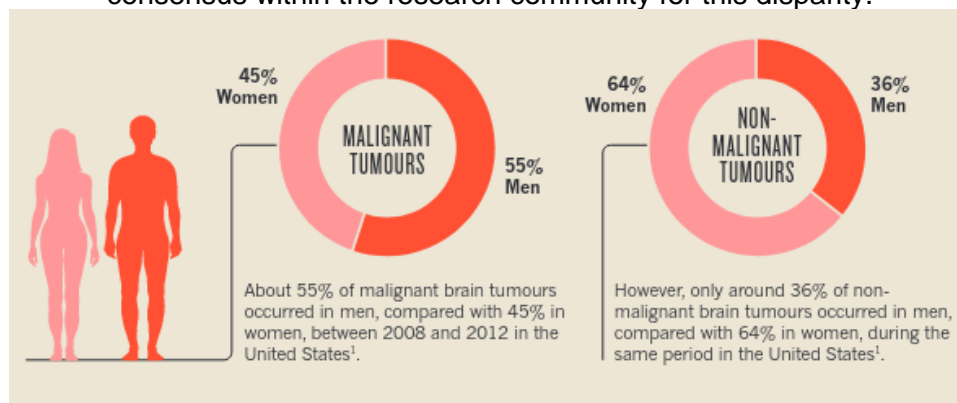


Figure 4



## 2.2.2 Clinical state of the art

Most brain tumors are diagnosed after symptoms appear. In general, diagnosing a brain tumor usually begins with magnetic resonance imaging (MRI). Once MRI shows that there is a tumor in the brain, the most common way to determine the type of brain tumor is to look at the results from a sample of tissue after a biopsy or surgery. Brain tumors, when compared to tumors in other areas of the body, pose a challenge for diagnosis. Radioactive tracers that may reach tumors in other areas of the body are unable to reach brain tumors until there was a disruption of the blood-brain barrier (BBB) by the tumor. Disruption of the BBB is well imaged via MRI, and is therefore regarded as the main diagnostic indicator for malignant gliomas, meningiomas, and brain metastases. Other common imaging modalities are CT and/or PET-CT.

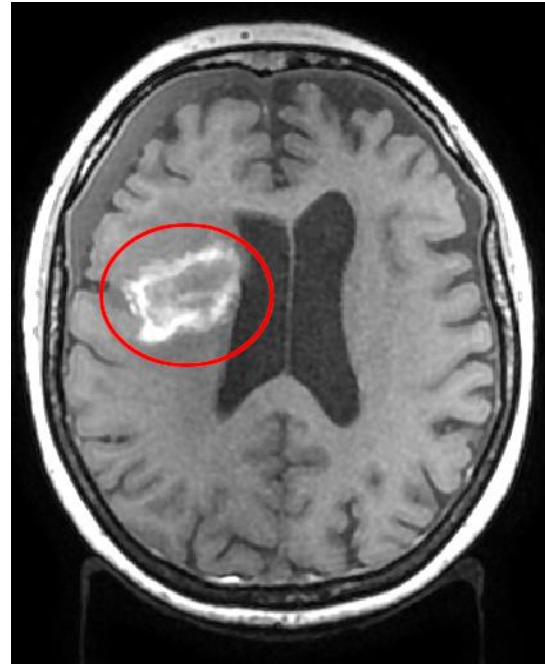

Figure 5

Robotic-assisted brain biopsy is becoming more common, but not considered standard. A robotic probe is the main tool for robot-assisted stereotactic tumor biopsy. It is interfaced with a computerized tomographic (CT) scanner and mounted at its end effector. Once the target is identified, a simple command moves the robot to a position pointing toward the target, which is a faster and more accurate procedure in comparison to the manually adjustable stereotactic frame biopsy. Appropriate preoperative imaging provides an anatomical roadmap to guide the biopsy needle to the exact target

A medical team generally assesses the treatment options and presents them to the person affected and their family. Various types of treatment are available depending on tumor type and location, and may be combined to produce the best chances of survival

### 2.2.2.1 Surgery

The primary and most desired course of action described in medical literature is surgical removal (resection) via craniotomy. Minimally invasive techniques are becoming the dominant trend in neurosurgical oncology. The main objective of surgery is to remove as many tumor cells as possible, with complete removal being the best outcome and cytoreduction of the tumor otherwise. A Gross Total Resection occurs when all visible signs of the tumor are removed, and subsequent scans show no apparent tumor. In some cases, access to the tumor is impossible and impedes or prohibits surgery.

Many meningiomas, with the exception of some tumors located at the skull base, can be successfully removed surgically. Most pituitary adenomas can be removed surgically, often using a minimally invasive approach through the nasal cavity and skull base (trans-nasal, trans-sphenoidal approach). Large pituitary adenomas require a craniotomy for their removal. Radiotherapy, including stereotactic approaches, is reserved for inoperable cases.



Robot assisted brain tumor resection is a novel field with and is typically not used in clinical routine.

### 2.2.2.2 Radiotherapy

Radiotherapy is the most common treatment for secondary brain tumors, but also commonly given as post-surgery for resected tumors in order to further improve local tumor control. Radiotherapy treatment planning is based on CT and/or MRI images, where the MRI images are used to outline the tumor as well as radiosensitive organs at risk (OAR). Delineation of OARs may either be manually or assisted by software. Software based OAR delineation software can either be based on deformation of atlases, but AI driven algorithms are becoming the norm. AI delineation of tumor is at the current time a research topic yet to make it into clinical practice.

The most common type of radiation treatment is called external-beam radiation therapy, which typically is directed at a brain tumor in the following ways:

- **3-dimensional conformal radiation therapy (3D-CRT)**  
Using images from CT and MRI scans, a 3-dimensional model of the tumor and healthy tissue surrounding the tumor is created. This model can be used to aim the radiation beams directly at the tumor, sparing the healthy tissue from high doses of radiation therapy.
- **Intensity modulated radiation therapy (IMRT)**  
IMRT is a type of 3D-CRT (see above) that can more directly target a tumor. It can deliver higher doses of radiation to the tumor while giving less to the surrounding healthy tissue. In IMRT, the radiation beams are broken up into smaller beams and the intensity of each of these smaller beams can be changed. This means that the more intense beams, or the beams giving more radiation, can be directed only at the tumor. Volumetric Modulated Arc Therapy (VMAT) is a subset of IMRT involving additional degrees of freedom in treatment delivery.
- **Proton therapy**  
Proton therapy is a type of external-beam radiation therapy that uses protons rather than x-rays. At high energy, protons can destroy tumor cells. Proton beam therapy is typically used for tumors when less radiation is needed because of the location. This includes tumors that have grown into nearby bone, such as the base of skull, and those near the optic nerve.
- **Stereotactic radiosurgery**  
Stereotactic radiosurgery is the use of a single, high dose of radiation given directly to the tumor and not healthy tissue. It works best for a tumor that is only in 1 area of the brain and certain noncancerous tumors.

IMRT, VMAT and Proton therapy is an optimization problem, where high tumor dose and low dose to surrounding OAR are conflicting objectives. Recently, AI tools aiming at either creating a treatment plan have emerged and have started to make their way into clinical routine.

### 2.2.2.3 Chemotherapy

Although chemotherapy may improve overall survival in patients with the most malignant primary brain tumors, it does so in only about 20 percent of patients. Chemotherapy is often used in young children instead of radiation, as radiation may have negative effects on the developing brain. The decision to prescribe this treatment is based on a patient's overall health, type of tumor, and extent of cancer. The toxicity



and many side effects of the drugs, and the uncertain outcome of chemotherapy in brain tumors puts this treatment further down the line of treatment options with surgery and radiation therapy preferred. Additionally, the BBB can prevent some drugs from reaching the cancerous cells.

### 2.2.3 Workflow inefficiencies and bottlenecks

- Imaging (both MRI and CT) are subjected to noise and artifacts. AI-based reconstruction algorithms have shown promising results, yielding images of higher quality from which diagnosis can be improved. [Diagnosis]
- Since prognosis is heavily linked to tumor progress, the largest benefit to patient outcome would be earlier diagnosis. It is plausible that AI models could play a role here. Research is ongoing in this field. [Diagnosis/Image interpretation]
- To further develop the tools for robot-assisted brain surgery, highly realistic models of the human brain are required — just as animal models of disease are needed to study treatments in patients. Deceased donors are often used to study human anatomy. But in this case, technological development must utilize a model of the brain that begins to bleed when you touch it, has cerebrospinal fluid and allows the conduction of current so that we can stimulate the brain model. [Robotics/Surgery]
- For radiotherapy, multimodal imaging is required, where MRI is used for delineation and CT for treatment planning. This poses a bottle neck as patients' needs to be imaged twice. Image fusion is also required, which adds an additional step. An MRI only workflow, where synthetic CT are generated from MRI and used as a drop-in replacement for CT have begun to become clinically accepted. [Treatment planning/Image fusion]
- The treatment planning process of external beam radiotherapy is time- and resource intensive. AI methods have been proven to yield equal results to manual delineation and planning with none or limited manual interaction. [Treatment planning]

### 2.2.4 End user goals and requirements

This paragraph lists the high level user goals and requirements for the brain tumour diagnosis and treatment.

- Generate synthetic CT images from MRI images [Image analysis].
  - High quality and accurate synthesised CT images
  - Should work as intended for any model of MR scanner
- AI-based segmentation of organs at risk [Image analysis/Diagnosis].
  - Quick and equally or better delineations of OAR relative to manual work
  - AI model trained on curated clinical annotations
- Platform for deployment of AI based software [Clinical workflow].
  - The platform shall be able to host generic AI applications
  - The platform shall be deployable in a clinical setting
- Automated treatment planning driven by AI [Treatment planning]
  - Quick and accurate treatment planning methods to improve patient care and save time

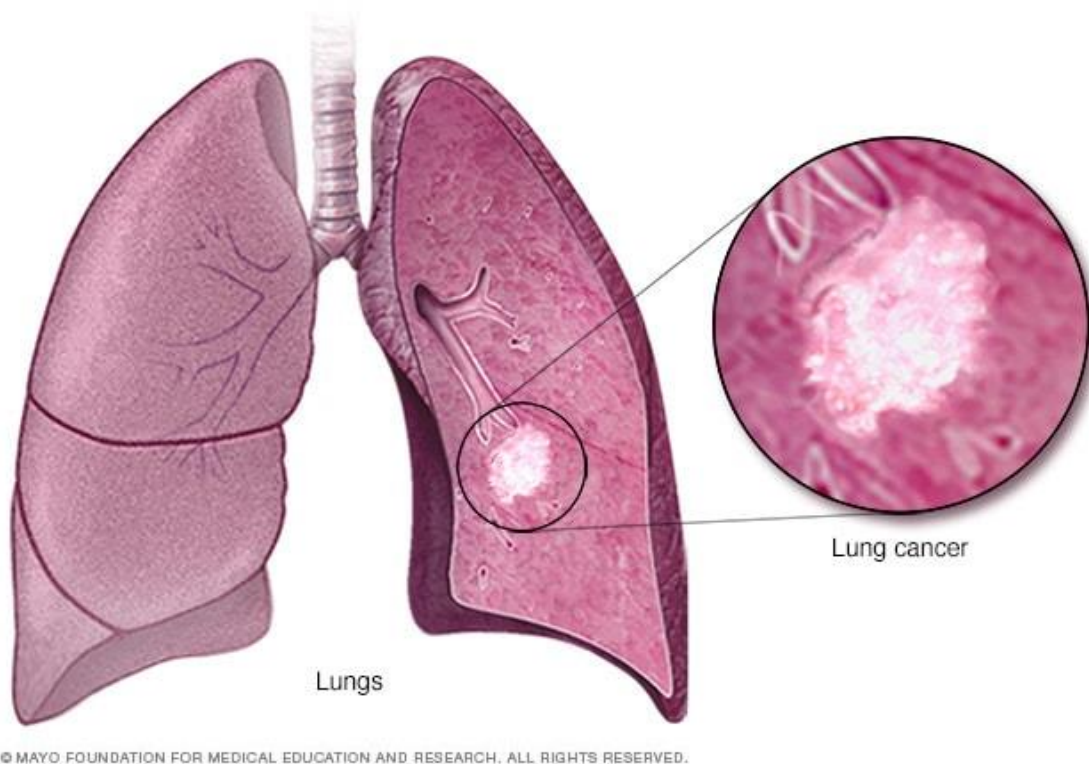




## 2.3 Lung Cancer

### 2.3.1 Introduction

Lung cancer is a common disease, with an incidence of 2.1M worldwide (2018). Worse, lung cancer is the leading cause of cancer death (18.4%, 1.7M, 2018 (IARC, 2018)). In addition to primary lung cancer, the lungs are also the second most frequent location of metastatic disease, with colorectal carcinoma, renal cell carcinoma and breast cancer most often metastasizing in the lungs (Society, 2019).



*Figure 6 Lung cancer originates from the cells in the lungs (Mayo, 2022)*

A common intervention to check a suspicious lung nodule, and detect and stage lung cancer is biopsy; tissue is obtained from the lung nodule either via the airways (using a bronchoscope), percutaneously (using a needle) or surgically. In the USA in 2006, some 75,000 bronchoscopic lung biopsies were performed, and 12,000 surgical lung biopsies.

In case lung cancer is confirmed, and depending on the lung cancer progression (stage), therapy will either be focused on curing the patient, or on improving quality-of-life for the patient. Several treatments are available, including surgery, systemic (chemo) therapy, radiation treatment, thermal ablation and immunotherapy. In general, there is a trend to more minimal invasive therapy.



### 2.3.2 Clinical state of the art

The journey of a lung cancer patient typically involves detection of symptoms / suspicious nodules, a biopsy procedure to confirm malignancy and stage the cancer, treatment planning, one or more treatments, and monitoring of the patient.

Patients may report with symptoms at their GP. Alternatively, patients may be invited to a lung screening because of their risk profile (heavy smoking, exposure to dust), and be flagged as having a suspicious lung nodule on a lung screening CT. In some cases, patients are flagged as having a suspicious nodule as an incidental finding on an ordinary thorax CT.

Typically, for a suspicious nodule larger than 10mm, a biopsy is planned to obtain tissue for pathology.

**MMWR** | **LUNG CANCER SCREENING SAVES LIVES**

**Lung Cancer is #1 Cause of Cancer Deaths**

Screening with low dose CT\* can detect lung cancer early and save lives

**More Screening is Needed**

7 of 8 adults who met screening criteria did not report recommended screening

**Healthcare Providers: Discuss Screening**

**With Adults**

- ✓ Age 55–80
- ✓ Heavy smoking history\*\*
- ✓ Smoke now or quit within the past 15 years

\*Low-dose computed tomography (CT) is the only test recommended by the US Preventive Services Task Force.  
\*\*Heavy smoking is a smoking history of 30 pack-years or more. A pack-year is smoking an average of one pack of cigarettes per day for one year.  
Data from BRFSS, 10 states in 2017, as reported in Richards et al, *MMWR* 2020 Read the full report: [bit.ly/CDCVA34](http://bit.ly/CDCVA34)  
CS 14820-8

WWW.CDC.GOV

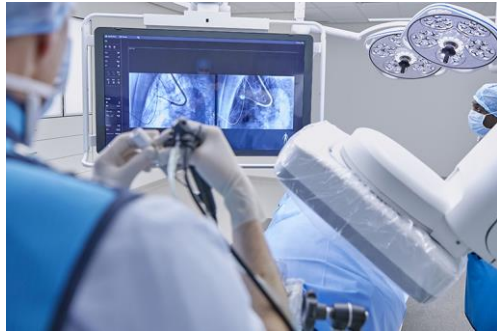Figure 7 Poster informing the public about the benefits of lung cancer screening (Prevention, 2017)

Endobronchial biopsies are the preferred way to obtain tissue. It is challenging to reliably obtain samples from small peripheral lung nodules (<20 mm), with diagnostic yield around 50% when solely using bronchoscope and 2D mobile C-arm. The alternative is to percutaneously obtain tissue using a long needle, guided by a CBCT or CT; this procedure has a higher risk of complications.

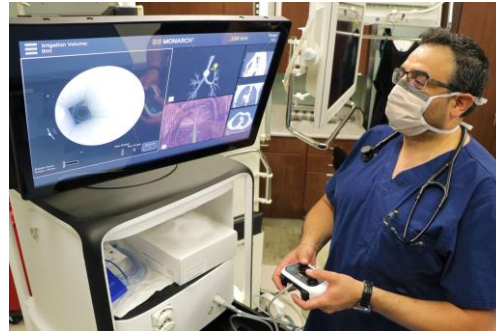Low DY is problematic because of the uncertainty and discomfort for the patient, and because delays in treatment increase mortality (mortality increases with 1% / week). Advanced endobronchial navigations systems (EBN), 3D CBCT imaging, and robotics are currently being adopted to increase diagnostic yield.

Also 'rapid on-site evaluation' (ROSE), an intra-procedural quick microscopic inspection of the tissue sample can improve diagnostic yield, by providing feedback to the pulmonologists that the sample was insufficient or taken from normal lung parenchyma instead of the suspicious nodule. This ROSE, however, cannot be used for diagnosis.





*Figure 8 Advanced endobronchial navigation with CBCT and augmented fluoro*



*Figure 9 Advanced endobronchial navigation with robotics*

After the biopsy, the sample tissue from the nodule, perhaps together with additional samples from the lymph nodes, are analysed by a pathologist. The pathology report is input to diagnosis and staging of the nodule.

The suspicious nodule might be diagnosed to be benign, for example, just an inflammation. Or it might be diagnosed as cancer. Lymph node samples help staging the nodule: the nodule might be small, isolated and early stage, corresponding to a good outlook for curative treatment. Or the nodule might be large, spread out and late stage, in which curative treatment might not be realistic, but palliative treatment can help lengthen survival and improve quality of life.

Various treatments are available, including surgical resection, chemotherapy, radiation therapy, and thermal ablation, the latter two being less invasive.

Thoracic surgery or surgical resection will aim to take away that part of the lung containing the cancer nodule, including sufficient margin (healthy tissue immediately surrounding the nodule, more likely to also include cancer cells).

Surgical resection is becoming less invasive, from open surgery requiring long recovery, towards key-hole surgery using an endoscope, with or without robotics. In addition, there is a trend to preserve more and resect less of the lung, going from resection of a complete lung to a lung lobes and to solely resecting a single lung lobe segment, provided the nodule is nicely located in a single segment.

Thermal ablation of the nodule is an established procedure when performed using ablation needles by the interventional radiologists. One or more needles are introduced via the skin (percutaneous) in or near the cancer nodule. Next, ablation is performed for five to ten minutes, heating or freezing the tissue in the surroundings of the needle tips in order to damage the cells. Over the next days and weeks, the nodule disappears, leaving only scar tissue in the lung.

The downside of using needles for ablation is the occurrence of pneumothorax (a minor complication).

Device vendors currently are trailing variants of these ablation device in the shape of flexible catheters which can be introduced via the airways by the interventional pulmonologist. These devices create the ability to treat the lesion in the same procedure as the biopsy, reducing waiting time and stress for patients.

Treatment follow-up typically is done using 3D imaging, CT and/or PET. Here, it is key to study the progression of the nodule, which ideally reduces in size. Image processing is key to help the radiologist register and overlay images from multiple sessions in order to assess the progression.



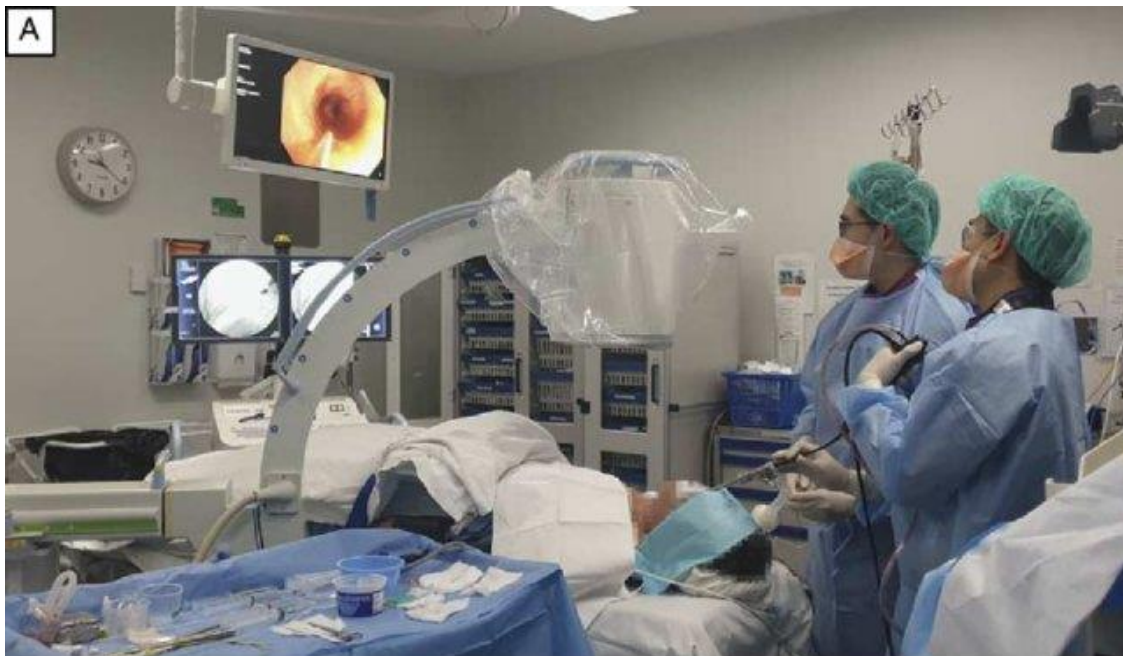### 2.3.3 Workflow inefficiencies and bottlenecks

The main workflow inefficiencies and bottlenecks consist of:

- The increasing inflow of lung screening scans and corresponding biopsies of small peripheral nodules
- Moving towards 'less invasive treatment' for lung cancer, reducing recovery time, burden and support needs required for patients

In order to cope with increasing inflow of lung screening scans, radiologists need help processing and diagnosing more scans.

Image processing software and computer assisted diagnosis play an important role in processing more chest CTs, for screening or incidental, without massively increasing the workload for the radiologists who is to read the CT scans. Suspicious nodules can be flagged automatically, as can CT scans who lack suspicious nodules.



*Figure 10 Traditional bronchoscopic lung biopsy with 2D fluoroscopy*

To cope with the increasing number of smaller, more peripheral, biopsies, interventional pulmonologists need assistance to increase the diagnostic yield (the ability to obtain a diagnostic tissue sample) while reducing procedure time.

These smaller peripheral nodules are often not 'fluoro-visible' (that is, they cannot be seen in 2D fluoroscopy X-ray imaging), are beyond the reach and vision of the bronchoscope, and may be in parts of the lung which are hard to reach (upper segments) or in parts of the lung which move a lot with breathing (lower segments, just above the diaphragm).

Without additional means to see the lesion, the biopsy device, and their relative positions, pulmonologists struggle to successfully obtain tissue from the suspicious nodule.

Advanced endobronchial navigations systems (EBN) track the biopsy device, and provide real-time feedback on the device position during navigation, using a pre-operative CT scan as reference. Use of EBN alone is associated with a modest increase in DY (from 50% to 70%). However, EBN systems are unable to see the



lesion, and suffer when the patient's lungs are deformed differently on the table during the biopsy than on the CT couch during pre-op CT imaging.

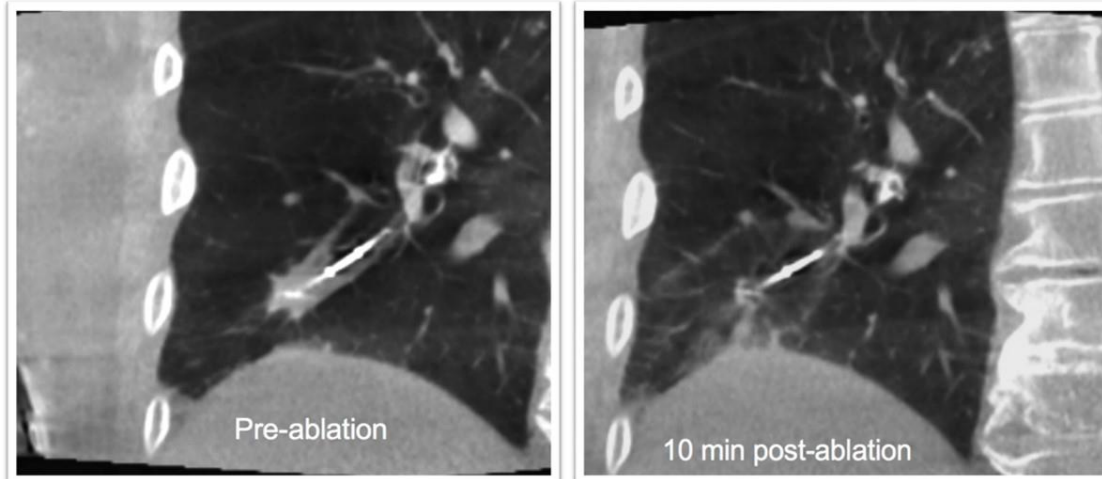
Three-dimensional cone-beam CT imaging systems are able to show the biopsy device and lesion and their relative positions in the lung. The lesion position may be overlaid on live fluoroscopy as a target (augmented fluoroscopy). Use of CBCT is associated with large increase in DY (to up to 90%).

The use of cone beam CT systems does present a significant learning curve for pulmonologists, though.

Endo-bronchial robotics support the pulmonologist with navigation and steerability, making it easier to navigate the catheter into hard to reach peripheral areas of the lung. Use of robotics alone is associated with a modest increase in DY (from 50% to 70%). Like EBN, robotics systems also are unable to see the lesion, and suffer from CT-to-body divergence.

In order to adopt 'less invasive treatments', various needs require addressing for the treatments.

To enable these smaller resections, more accurate information about the lung (fissures, vasculature) needs to be made available during the surgery. This requires both improved (AI-based) segmentation algorithms to extract detailed anatomic information from pre-op images. And a translation of the anatomic information to patient on the table during the intervention, where the lung might be collapsed and flipped.



*Figure 11 MW ablation via an endobronchial catheter (device in clinical trial)*

To enable adoption of novel endobronchial ablation devices, interventional pulmonologist need planning and guidance software to help them identify the ablation positions offering sufficient coverage of the lesion and margin, both on pre-op CT and on in-op CBCT.



### 2.3.4 End user goals and requirements

The end user goals and requirements are listed below and structured in four categories.

The anticipated solution shall support efficient early detection of suspicious nodules in lungs.

- Computer assistance in flagging lung screening CT and incidental CT scans that do not / may include suspicious nodules and do not / require further reading by a radiologist

Assistance in planning complex biopsies and minimally invasive treatment procedures

- AI algorithms to segment and label anatomy on pre-op CT scans, to enable the physician to plan optimal access and paths to the lesion, and to plan minimal resections

Improved diagnostic yield from endobronchial biopsies for small lung nodules

- Navigation guidance towards small peripheral nodules beyond the view of the bronchoscope
- 3D tool-in-lesion confirmation
- Steerable catheters to access hard to reach locations in the lung
- Compensation for pre-op CT to in-op body divergence
- Short learning curve and simple UI to enable interventional pulmonologists to adopt these new solutions

Assistance in minimal invasive treatments

- 3D visualization of the anatomy as reference during the minimally invasive key-hole resections
- Support for planning ablation zones and for optimizing ablation parameters prior to and during endobronchial ablation procedures
- Support for assessing ablated zones during the intervention, in order to correct insufficient coverage of lesion and margin with an addition ablation

## 2.4 Hepato Pancreato Biliary oncology (HPB)

Owner: LUMC – Jouke Dijkstra

### 2.4.1 Introduction

Pancreatic cancer is 4th leading cause of cancer death in the United States. Prognosis is very poor with median survival of < 6 month in advanced cases. Upon diagnosis, the disease is associated with a 5-year survival rate ~10%. Surgical resection is the only curative option with an associated 5-year survival rate of up to 20-30% depending on the tumor size. However, discriminating between malignant and benign tissue can be challenging, especially after neoadjuvant treatment due to therapy induced fibrosis (TIF). In the same anatomical region cholangiocarcinomas arising from the epithelial lining of the biliary tree, are more rarely seen, they account for around 2% of all malignancies. They belong to a cluster of highly heterogeneous biliary malignant tumors that can arise at any point of the biliary tree.

Cholangiocarcinomas are categorized according to anatomical location as intrahepatic (iCCA), perihilar (pCCA), or distal (dCCA). pCCA and dCCA can also be collectively referred to as 'extrahepatic' (eCCA). Prognosis, like in pancreatic cancer is very poor,



due to silent presentation with advanced disease. Median survival was 10 months unrelated of stage of disease and with a 1-year and 5-year survival rate of 46% and 11%, respectively. As well as in pancreatic cancer complete surgical resection is the only possible curative option. Hence, the related anatomical location and morphological composition of extrahepatic cholangiocarcinomas (eCCA) and pancreatic (head) cancer, this is an interesting field of research for fluorescence guided surgery with tumor targeted fluorophores.

Currently, enhancing contrast of structures using near-infrared (NIR) fluorescence is a technique under development. It can provide accurate and real-time visualization of tumors during surgery. Fluorescent agents are intravenously administered and specifically bind to malignant cells or tumor-associated tissue, such as neoangiogenic vessels or stroma, and emit light in the invisible, near-infrared spectrum (i.e. 700-900 nm). Using a dedicated fluorescence imaging system, contrast of tumors relative to their background can be improved, which allows real-time image-guided surgery and improve complete resection rates. cRGD-ZW800-1 is a fluorescent contrast agent that specifically binds to integrins associated with neo-angiogenesis. It is a cyclic pentapeptide (cRGD) conjugated to the 800 nm NIR fluorophore ZW800-1. The cyclic 3-amino acid sequence (RGD) is clinically a well-known peptide that binds to various integrins ( $\alpha\beta1$ ,  $\alpha\beta3$ ,  $\alpha\beta5$ ,  $\alpha\beta6$ ,  $\alpha\beta8$ ,  $\alpha5\beta1$ ,  $\alpha8\beta1$  and  $\alpha11\beta3$ ), mostly associated with neo-angiogenesis. Tumors larger than 1-2 mm depend on the formation of new blood vessels to acquire sufficient amounts of oxygen and nutrients. Some of these integrins are overexpressed on malignant cells and in tumor stroma, such as in breast, colorectal, pancreas and lung cancer. cRGD-ZW800-1 has successfully been used in colorectal cancer patients, identifying colorectal cancer during oncologic resection. Other RGD based molecules have been investigated in various phase I and phase II imaging studies using PET and SPECT and in a phase III study as an anticancer therapy (cilengitide). Recently, our group has initiated a phase II clinical trial investigating the application of a cRGD targeted PET tracer ( $^{18}\text{F}$ -Fluciclatide) in the response monitoring of pancreatic cancer.





### Estimated New Cases

		Males		Females		
Prostate	248,530	26%		Breast	281,550	30%
Lung & bronchus	119,100	12%		Lung & bronchus	116,660	13%
Colon & rectum	79,520	8%		Colon & rectum	69,980	8%
Urinary bladder	64,280	7%		Uterine corpus	66,570	7%
Melanoma of the skin	62,260	6%		Melanoma of the skin	43,850	5%
Kidney & renal pelvis	48,780	5%		Non-Hodgkin lymphoma	35,930	4%
Non-Hodgkin lymphoma	45,630	5%		Thyroid	32,130	3%
Oral cavity & pharynx	38,800	4%		Pancreas	28,480	3%
Leukemia	35,530	4%		Kidney & renal pelvis	27,300	3%
Pancreas	31,950	3%		Leukemia	25,560	3%
<b>All Sites</b>	<b>970,250</b>	<b>100%</b>		<b>All Sites</b>	<b>927,910</b>	<b>100%</b>

### Estimated Deaths

		Males		Females		
Lung & bronchus	69,410	22%		Lung & bronchus	62,470	22%
Prostate	34,130	11%		Breast	43,600	15%
Colon & rectum	28,520	9%		Colon & rectum	24,460	8%
Pancreas	25,270	8%		Pancreas	22,950	8%
Liver & intrahepatic bile duct	20,300	6%		Ovary	22,950	5%
Leukemia	13,900	4%		Uterine corpus	12,940	4%
Esophagus	12,410	4%		Liver & intrahepatic bile duct	9,930	3%
Urinary bladder	12,260	4%		Leukemia	9,760	3%
Non-Hodgkin lymphoma	12,170	4%		Non-Hodgkin lymphoma	8,550	3%
Brain & other nervous system	10,500	3%		Brain & other nervous system	8,100	3%
<b>All Sites</b>	<b>319,420</b>	<b>100%</b>		<b>All Sites</b>	<b>289,150</b>	<b>100%</b>

Figure 12 (Siegel, 2021)

## 2.4.2 Clinical state of the art

The diagnostic workup for PDAC typically consists of a combination of CT for staging and endoscopic ultrasound with fine needle aspiration (EUS-FNA) or biopsy or endoscopic retrograde cholangiopancreatography (ERCP) to obtain histological confirmation of disease. Recently, magnetic resonance imaging (MRI) has gained ground for the primary evaluation of local disease stage and vascular encasement by tumor tissue, as well as the characterization of distant metastases, especially in the peritoneal cavity and liver. The role of 18F-FDG positron emission tomography (PET) combined with computed tomography (PET/CT) in the workup of pancreatic cancer remains controversial. The National Comprehensive Cancer Network (NCCN) consensus guideline states that FDG-PET/CT may be used per institutional preference; although, it is not a substitute for high-quality contrast-enhanced CT (ce-CT). The European Society for Medical Oncology (ESMO) states likewise and says the role of PET/CT should be further clarified. The individual treatment plan is based on various clinical and radiological parameters, including tumor stage, the presence of metastatic disease, the extent of tumor invasion into major blood vessels, and the patient's physical condition.

Determination of resectability of a pancreatic tumor with clear surgical margins is crucial, as only complete surgical resection of the tumor can provide curative-intent



treatment. Constantly developing surgical techniques (e.g., robot-assisted surgery) and the clinical introduction of (neo)adjuvant therapy have significantly improved patient outcomes in the past decade, resulting in a 30–40% five-year OS after complete (R0) tumor resection, compared to 17.4% in 2011. The incomplete surgical resection rates (R1 or up) vary enormously in the available literature, between 20 and 70% of all pancreatic resections for malignant disease show positive surgical margins, which dramatically increase the rate of local and early recurrence of pancreatic cancer. Aiming to increase the number of patients eligible for curative-intent resection and to further optimize surgical outcome, the combination of neoadjuvant induction therapy and adjuvant treatment has been under clinical investigation in the past years. There are currently two combinations recommended as first-line (neo)adjuvant treatment regimens by the NCCN and ESMO: (modified) FOLFIRINOX (Folic acid, 5-Fluoruracil, Irinotecan, and Oxaliplatin) or gemcitabine plus nab-paclitaxel, the last is often combined with radiation therapy. Since individual patient health status and morbidity highly influence the ability to receive (neo)adjuvant treatment, most well-considered multidisciplinary recommendations for duration and intensity of treatment are made within these standardized regimens or ongoing clinical trials for individual patients.

Focusing on neoadjuvant therapy (NT), the most clinical benefit could be gained within the borderline resectable and locally advanced patients; however, a standardized role in primary resectable disease should also be considered. NT aims to slow disease progression, decrease tumor volume and local extensiveness, as well as eradication of potentially 'occult' micrometastases. NT, on one side, provides an extended time-window to detect rapid progressive disease, thereby potentially avoiding futile surgeries. On the other side, it provides a way to increase the eligibility for curative-intent resection, raise the percentage of radical resections (R0) and improve the surgical outcome. The advantages of NT are underlined by the results of the recently published PREOPANC-1 trial. This trial compared clinical outcome and survival data of postoperative patients with resectable and borderline resectable disease who had received neoadjuvant or adjuvant therapy. Results showed improved survival and higher complete surgical resection (R0) rates in the neoadjuvant therapy arm, with a 30% increase in R0 resections (71% vs. 40%) and a 2-month prolonged median survival (16 vs. 14 months) [18]. More recently, the recruitment of patients for its successor, the PREOPANC-II trial (NTR7292) was completed. In this trial neoadjuvant treatment with FOLFIRINOX was compared to neoadjuvant Gemcitabine-Radiotherapy followed by adjuvant Gemcitabine in patients with (borderline) resectable disease.

To date, accurate assessment of response to (neo)adjuvant treatment remains challenging, which is a crucial step in re-staging and determination of resectability. Currently, treatment response is monitored with CT-imaging, which is evaluated by radiologists using the internationally standardized RECIST 1.1 criteria. These criteria focus on a percentual change in tumor dimensions (longest diameter), which are used to determine therapy response: a complete response (CR), partial response (PR), progressive disease (PD), or stable disease (SD). Although the role of this approach for assessment of response is limited, besides overestimation of tumor size on CT, the change in tumor attenuation is of limited value in the prediction of resectability, due to the inability to differentiate treatment-related necrosis, therapy-induced fibrosis (TIF), and tumor-associated pancreatitis (TAP) from residual vital tumor tissue in the pancreas. Cassinotto et al. concluded ce-CT lacks the sensitivity and performance for accurately monitoring treatment response, showing that the diagnostic performance of





ce-CT to predict resectability decreased after neoadjuvant treatment (58% vs. 83%). Ferrone et al. showed similar results, stating that ce-CT after FOLFIRINOX treatment no longer adequately predicts resectability of the tumor. These results underline the need for improved imaging methods for assessment of therapy response, since this is pivotal for accurate (re)staging and determination of tumor resectability. In addition to conventional CT-imaging, molecular-based FDG-PET/CT-imaging has been evaluated for monitoring of (neo)adjuvant treatment response in various malignancies, including PDAC. Despite some favorable results, the main disadvantage of FDG-based PET/CT-imaging of pancreatic tissue is the increased uptake seen in TAP, complicating adequate differentiation between the remaining tumor and adjacent benign tissue. Molecular-targeted tumor imaging has the potential to overcome these challenges by selectively targeting tumor biomarkers overexpressed on or in close proximity to PDAC cells, resulting in high tumor-specific signals with minimal background accumulation in surrounding normal tissue.

Following induction treatment and restaging, the next vital steps for curative intent resection are: intraoperative visualization and delineation of the tumor to its anatomical demarcations and relations with vital structures, identification of suspect tumor-containing lymph nodes, as well as assessment of the surgical margins for residual vital tumor. However, the complex and heterogeneous tumor characteristics of PDAC with its extensive desmoplastic reaction and locoregional changes resulting from NT as well as its retroperitoneally anatomical location make this very challenging. Near-infrared fluorescence (NIRF) imaging, also called fluorescence-guided surgery (FGS), a novel technique, can offer a solution by providing real-time intraoperative guidance by enhancing visual contrast for localization of the tumor and discrimination between malignant and benign tissue. FGS uses a fluorescent dye conjugated to a molecular tracer designed to bind specific molecular features on (tumor)-target cells (i.e., tumor tissue, tumor stroma, etc.). Aiding a surgeon with a tool that enhances intraoperative surgical navigation to detect tumor, lymph node, and metastatic deposits in real-time, might eventually result in fewer incomplete surgical resections (R1) and improve surgical outcome and OS in the near future.

Multiple molecular targets, or biomarkers, expressed by PDAC, have been identified in previous studies. These biomarkers form the basis for tumor-targeted nuclear and fluorescence imaging in various malignancies, including PDAC. Molecular imaging of oncological targets has been of particular interest in the past decade: multiple (pre)clinical trials have shown promising results for PDAC-targeted PET/CT and NIR-imaging, for diagnostic as well as therapeutic purposes.

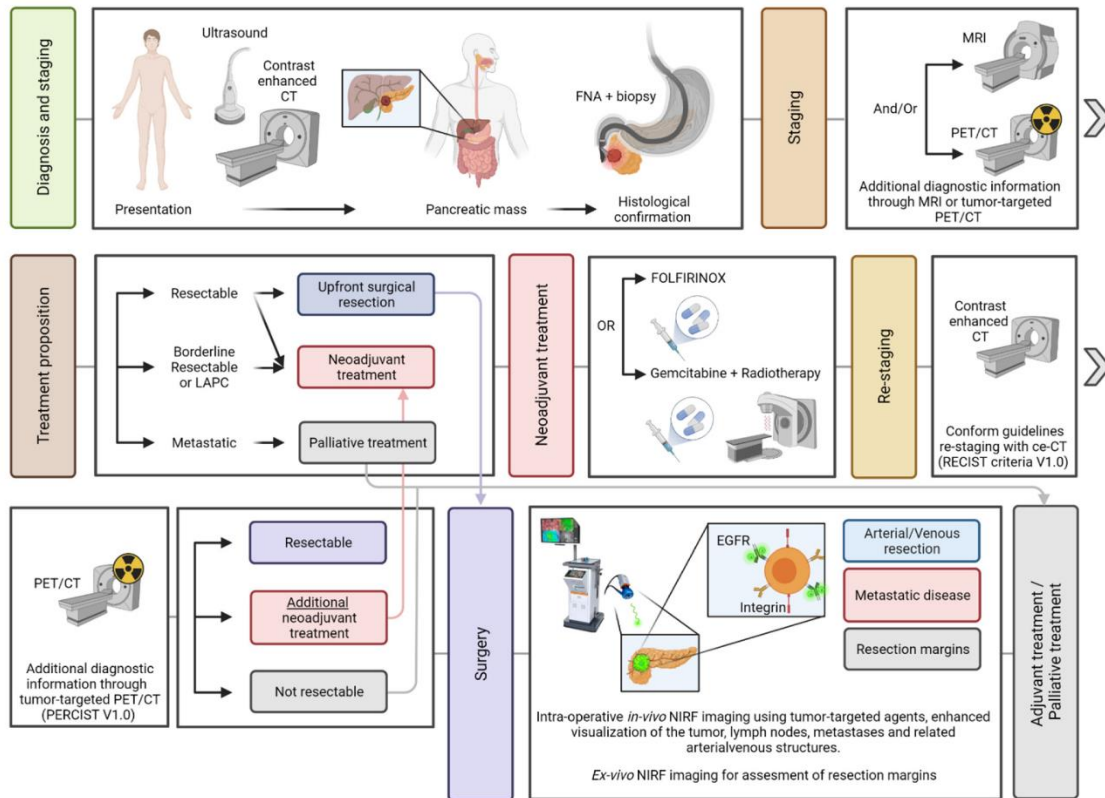


Figure 13 (van Dam, 2021)

### 2.4.3 Workflow inefficiencies and bottlenecks

- Quality of the scans for tumor delineation:
  - As described previously both CT and MR imaging have limited value in assessing vascular involvement. Therefore patients are incorrectly deemed irresectable;
- Accuracy of assessment of distant and nodal metastases for treatment planning:
  - MR imaging is more sensitive for the detection of liver metastases, however, CT imaging has shown to be superior to MR imaging in the detection of nodal metastases;
- The complexity of correct restaging after neoadjuvant chemotherapy which is important for selection of optimal treatment option:
  - Differentiation between fibrosis and malignant tissue is challenging after neoadjuvant chemotherapy;
- Interpretation of 2-dimensional scans remains challenging, especially in determining the circular involvement of the vital blood vessels surrounding the pancreas, i.e. mesenteric superior vein, mesenteric superior artery, celiac artery and the portal vein:
  - Creating VR or AR 3D models of preoperative imaging may lead to more accurate planning and surgery;
- Co-registration of preoperative imaging with intraoperative ultrasonography:
  - Due to breathing and subsequent deformation of the organ this remains challenging;



- The challenge of determining known lesions in follow-up images, for monitoring purposes:
  - Early tumor recurrence may be hard to identify on current anatomical imaging modalities such as CT and MR imaging. Therefore, combining several imaging techniques could increase sensitivity and specificity for the detection of residual disease and early recurrence;
- The limitations of RECIST tumor evaluation:
  - CT and MR imaging have several limitations, therefore the addition of PET-CT may be of significant value to more accurately assess tumor's response to neoadjuvant chemotherapy.

#### 2.4.4 End user goals and requirements

For the HPB use case, software tools are needed for better diagnostics and treatment planning. This involves accurate segmentation of the HPB organs and the detection of malignant regions. This results in the next requirements, which are also linked to the different work packages in ASSIST.

##### Imaging and image analysis for diagnosis

- The software tools should be able to segment the HPB organs.
- The software tools should be able to register MRI and CT data sets from the same patient from the same time point to improve the segmentation.
- The functional information from PET-CT, if available, should be added to the fused MRI and CT images.
- The tumour detection should use image information from both CT and MRI to improve the sensitivity and specificity.
- The software tools should be able to classify fibrotic and malignant within the organ of interest.

##### Treatment planning

- The software tools should be able to segment the important vessel around the organ of interest.
- The software tools should be able to calculate the vascular involvement for the pancreas tumour.
- The software tools should be able to compare pre- and postoperative scans.

##### Robotic assistance

- The preoperative imaging should be registered to the intraoperative ultrasonography to compensate for breathing and deformation.

##### 3D visualization

- The software tools should be able to visualize the vascular involvement, in visual maps and in numbers.
- The software tools should be able to produce a 3D volume, which shows the essential structures which can be used by VR or AR for planning and surgery.



## 2.5 Prostate enlargement

Owner: Fortearge – Serdar Sultanoglu

### 2.5.1 Introduction

Prostate enlargement, also called Benign prostatic hyperplasia (BPH), is a noncancerous increase in size of the prostate gland. (BPH), proliferation of the glandular and stromal tissue in the transition zone of the prostate, results in lower urinary tract symptoms (LUTS) and bladder outlet obstruction.

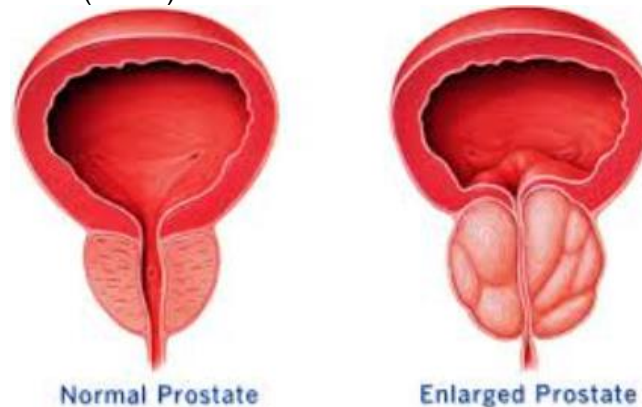


Figure 14 Normal vs Enlarged Prostate (A1, 2014)

The prevalence increases with age and 25% of men older than 70 years old have moderate to severe LUTS that effect their quality of life (QoL). About 105 million men are affected by BPH globally. It typically begins after the age of 40. Half of males age 50 and over are affected. After the age of 80 about 90% of males are affected.

A wide variety of medical and surgical options are available for the management of BPH with LUTS. In patients with moderate to severe LUTS refractory to medical management more invasive treatments are considered. Transurethral resection of the prostate (TURP) and open prostatectomy (OP) are the gold standard treatment methods for prostate glands of 30-80 cm<sup>3</sup> and ≥ 80 cm<sup>3</sup> respectively. However, these procedures have considerable morbidity rates including retrograde ejaculation, erectile dysfunction, urethral stricture, urinary retention, transfusion requirement and incontinence. Also in patients with existing comorbidities, increasing age and large prostate volume the complication rates are higher and hence the eligibility for surgical therapies are limited.

The primary goal of BPH treatment is to prevent or reverse urinary complications by improving LUTS.

Medical and surgical options are available; however, these procedures have considerable morbidity rates. Prostate artery embolization (PAE) has emerged as a minimal invasive treatment method which has a lower risk of urinary incontinence and sexual side effects.

The PAE procedure involves intra-arterial delivery of embolic materials to block the blood vessels supplying the hypertrophied transitional zone in the prostate gland. In order for the PAE treatment to be successful, an in-depth analysis of the patient should be made before the procedure. In order for the procedure to be technically successful, accurate determination of the anatomy of the prostate arteries and adequate embolization of the target are required. This procedure should avoid non-target embolization (NTE) to other tissues, soft tissue of the bladder and rectum and penis, and other critical structures in the pelvis.



## 2.5.2 Clinical state of the art

Lifestyle changes and behavioural interventions are used to treat BPH in patients with mild symptoms. When the treatment does not work, medical means are used. Medical treatments that can be used to treat Alpha-blockers, 5-alpha reductase inhibitors, anticholinergics, and phosphodiesterase inhibitors include pills, injections, or patches. Many patients with BPH also have other health problems that make their LUTS worse. Some patients experience a series of serious adverse events, including irreversible sexual dysfunction, mood changes, and neurological and cognitive complaints that persist despite drug discontinuation. There are some limits to how much compliance people have with medical treatment, with 10% to 30% of people meeting treatment goals after one year. 25% of patients do not respond to medical treatment, especially those with major glands at baseline. Some medical treatments have little effect, making patients turn to surgery as their only recourse. This can be problematic because surgery is often less effective and can lead to bad side effects. (Gabr, 2021)

Surgical treatments that have developed over time include steam thermotherapy, prostate urethral lift, prostate ablative treatments (for example, monopolar transurethral resection of the prostate [M-turp], bipolar transurethral resection of the prostate [B-turp], transurethral electrovaporisation of the prostate [Tuvp], photoselective evaporation of the prostate) [Pvp], Holmium laser laser simple prostatectomy plus enucleation of the prostate [Holep] and thulium laser enucleation of the prostate [Thulep]). Surgical treatments have limitations, such as the need for general anaesthesia, foley catheterization, and a high rate of postoperative sexual dysfunction. There is variability in the success rates of surgical treatments for prostate cancer, depending on the size of the prostate gland. (Gabr, 2021)

A wide variety of medical and surgical options are available for the management of BPH with LUTS. In patients with moderate to severe LUTS refractory to medical management more invasive treatments are considered. Transurethral resection of the prostate (TURP) and open prostatectomy (OP) are the gold standard treatment methods for prostate glands of 30-80 cm<sup>3</sup> and ≥ 80 cm<sup>3</sup> respectively. However, these procedures have considerable morbidity rates including retrograde ejaculation, erectile dysfunction, urethral stricture, urinary retention, transfusion requirement and incontinence. Also in patients with existing comorbidities, increasing age and large prostate volume the complication rates are higher and hence the eligibility for surgical therapies are limited.

Prostate artery embolization (PAE) has emerged as a minimal invasive treatment method for the management of LUTS attributed to BPH. Although in the literature many data consisting of retrospective cohorts and few prospective studies exist, PAE has still not found its place in urological guidelines. FDA at the US recently approved PAE as an alternative treatment for LUTS related to BPH.

When considering PAE the technique is the challenging part requiring experience in recognizing prostatic arteries and avoiding non target embolization. As male internal iliac anatomy is prone to variations so are prostatic arteries which they can vary in origins, number. Besides, usually during treatment, cone beam CT is required especially with less experienced operators/angiographers. Many different protocols exist among centers for workup before the procedure to recognize and plan treatment including pre-operative CT imaging, MR imaging or no pre-imaging at all.



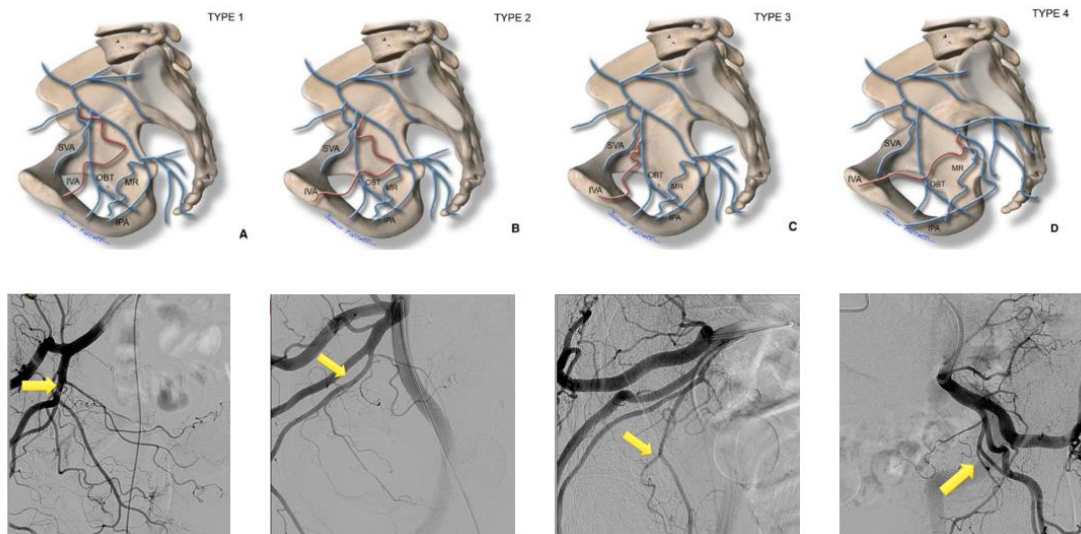


Figure 15 Variations in prostatic arteries

Pre-treatment non-contrast CT usually contributes little to the evaluation of prostate gland ultrasound or MRI. However, some clinicians wish to obtain a preprocedural computed tomography angiogram (CTA) to assess the extent of iliofemoral atherosclerosis and prostate artery anatomy to plan treatment. The reason is the data obtained that this technique will reduce the procedure time.

Pre-treatment computed tomography angiography is an imaging technique that can help identify prostate arteries and help plan prostate-artery embolization (PAE). The specificity of artery identification may decrease by 59% because of imaging protocols/parameters. A higher sensitivity to the magnetic resonance-inflationary pulse was found. (Carnevale FC, 2020) To identify the vascular patterns, an arterial CT angiography scan could be performed (2 mL/sec, with 4-6 seconds delay). Careful analysis of proximal cone-beam computed tomography (CBCT) datasets can identify arteries feeding the gland and other nontarget vessels. Segmentation of the pelvic and prostate vasculature and arteries of interest, both gland feeders and nontarget vessels, allows creating a 3D model that can be used for advanced guidance. (Carnevale FC, 2020) To identify the vascular patterns, an arterial CT angiography scan could be performed (2 mL/sec, with 4-6 seconds delay).

Other most common tool in cone-beam CT angiography which is obtained during the DSA for PAE. So, the patient is already on the table for PAE and CBCT is used as a complimentary imaging tool to identify the prostatic artery or other non-target branches. Careful analysis of proximal cone-beam computed tomography (CBCT) datasets can identify arteries feeding the gland and other nontarget vessels.

Segmentation of the pelvic and prostate vasculature and arteries of interest, both gland feeders and nontarget vessels, allows creating a 3D model that can be used for advanced guidance. (Carnevale FC, 2020)

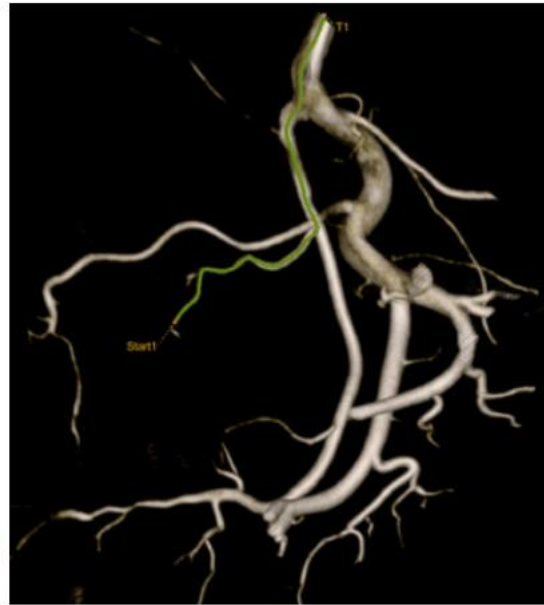

Figure 16 A 3D reconstruction model of the left internal iliac artery branches was automatically segmented. The prostate artery and catheterization path are highlighted in green. (Carnevale FC, 2020)

Virtual 3D anatomical data can be obtained using augmented reality and AI-based CT, CBCT or MRI. This is the fusion of real-world 2D visual images, creating a virtual device trajectory superimposed on the visual surface anatomy. Theoretically, accurate navigation can be achieved without the need for fluoroscopy. (Gurgitano M, 2021)

Thanks to the integrated matching AI software, automatic landmark recognition and motion compensation can be enabled using reference markers linked by a computer algorithm. This system can be applied in lesion targeting/localization, spinal/paraspinal injections, arthrograms, tumour ablation, bone biopsies and more recently minimally invasive surgical procedures. (Gurgitano M, 2021)

### 2.5.3 Workflow inefficiencies and bottlenecks

- Complexity of the technique
  - When considering PAE, the challenging part in this technique requires experience in recognizing prostatic arteries and avoiding non target embolization. As male internal iliac anatomy is prone to variations so are prostatic arteries which they can vary in origins, number.
  - Non-target embolization is a potential drawback of the procedure.
- Need for expensive medical devices
  - Pretreatment CTA is more accessible
  - Usually during treatment, cone beam CT is required especially with less experienced operators/angiographers. Although not every IR has it with angio units, it is becoming a must have tool with DSA in the last 10 years.
- Longer operation time
  - The shorter the operation time, the higher the patient satisfaction. During the procedure, the physician's time to find the target artery increases the operation time.





- Excess radiation exposure
  - Since automatic artery identification cannot be performed in the current situation, the patient is examined with more imaging techniques.
- The clinician should combine many data before the procedure
  - While making a diagnosis, many tests applied to the patient should be combined and understood by the clinician. This is a difficult procedure for the clinician. If the clinician is given the fusion of all image data, it becomes easier for the clinician to diagnose and plan treatment.
- Late diagnosis
  - The clinician's difficulty in combining many data affects the time to diagnosis. Early diagnosis is extremely important in terms of planning the treatment process of the patient.
- Experienced physician requirement
  - Prostatic Artery Embolization is a difficult process, so it is not possible for all clinicians to perform it. Due to the difficulties mentioned in the previous articles before and after the treatment, experienced doctors are expected to perform the treatment.

#### 2.5.4 End user goals and requirements

End user goals and requirements of prostate enlargement use case are listed below organized based on current clinical bottlenecks.

- Complexity of the technique
  - Clinician should be able to easily locate the prostate artery for PAE in the very complex iliac territory thanks to suggestions of AI based automatic artery detection function. When the artery is detected, which is the most important part of the operation, the clinician's role in the treatment is alleviated.
- Need for expensive medical devices
  - Clinician should be able to detect the prostate artery with DSA image without the need for more limited and expensive image sources such as MRI and CT. By using more accessible medical imaging devices, the clinician does not need to use complex, expensive and difficult-to-access devices in the diagnosis phase. The clinician should be able to use simple medical imaging devices such as DSA for imaging the prostate and prostate artery, as it will be easier to access them.
- Objective evaluation of treatment
  - Clinician should be able to segment and objectively quantify prostate gland automatically. During treatment planning, the clinician requests that the prostate segmentation of the patient is performed, and objective data of the prostate be obtained automatically.
  - Clinician should be able to evaluate the effectiveness of the PAE treatment by comparing the objectively quantified data at certain times. The prostate size should be compared by measuring the prostate enlargement of the patient before and after PAE.
- Clinical productivity & speed
  - Clinician should be able to spend less time in diagnosis and treatment planning by using the PAE assistant software's automatically generated results and user-friendly interfaces.



- Clinician should be able to complete the PAE treatment in a shorter time with this technology.
- Experienced physician requirement
  - Less experienced clinicians also should be able to complete perform PAE treatment.
  - The automatic prostate segmentation, automatic detection of the prostate artery, and the ready availability of objective prostate measurements do not require the physician to devote many years to this treatment.



### 3 Conclusions

This document defines and details the use case areas of the ASSIST project which are brain tumors, intracranial hemorrhage, lung diseases, hepato-pancreato biliary-oncology (HPB) and prostate enlargement. Each use case is detailed in its specific section. The summary of the use case is given in the introduction section. In the following section, state-of-the-art related to the latest technological developments and clinical status are described, covering diagnostic and therapeutic workflows, input data for workflows, uses of robotic assistance and 3D visualization, and uses of AI tools and software. In the next section, workflow inefficiency and bottlenecks in improving the clinical workflow of the state-of-the-art product are expressed. The last section defines the requirements from the end-user's perspective.

Looking at all use cases, common requirement areas can be extracted as interoperability and standards compliancy in medical data access, near clinician performance of SotA AI techniques in diagnosis and treatment planning, addressing of low volume of medical data problem and visualization of complex medical data and generated results.

The end user needs from all uses cases reinforces the core idea of the project that clinicians need assistance in modern clinical circumstances with high load of data and performance expectations.



## 4 REFERENCES

- A1, F. (2014).
- Béjot, Y. B. (2016). Epidemiology of stroke in Europe and trends for the 21st century.
- Burduja, M. I. (2020). Accurate and Efficient Intracranial Hemorrhage Detection and Subtype Classification in 3D CT Scans with Convolutional and Long Short-Term Memory Neural Networks. *Sensors* (s. 5611). içinde
- Caceres, J. &. (2012). Intracranial Hemorrhage. *Emerg Med Clin North Am* (s. 771-794). içinde
- Carnevale FC, d. A. (2020). Prostatic Artery Embolization: Equipment, Procedure Steps, and Overcoming Technical Challenges. *Techniques in Vascular and Interventional Radiology*.
- Clinic, M. (tarih yok). *Stroke - Diagnosis and treatment - Mayo Clinic*.
- Fernando, S. M. (2018). Outcomes and Costs of Patients Admitted to the ICU Due to Spontaneous Intracranial Hemorrhage. *Critical Care Medicine* (s. 395-403). içinde
- Gabr, A. S. (2021). Contemporary Review of Prostate Artery Embolization for the Treatment of Benign Prostatic Hyperplasia: Technical Considerations and Long-Term Outcomes. *Advances in Clinical Radiology*.
- Gurgitano M, A. S. (2021). Interventional Radiology ex-machina: impact of Artificial Intelligence on practice. *La radiologia medica*.
- Hosseini, M. J. (2017). A Mobile Geo-Communication Dataset for Physiology-Aware DASH in Rural Ambulance Transport. *Proceedings of the 8th ACM on Multimedia Systems Conference*.
- Hssayeni, M. C.-k. (2020). Intracranial Hemorrhage Segmentation Using a Deep Convolutional Model. *Data* (s. 14). içinde
- IARC. (2018). *Latest global cancer data*:. World Health Organization.
- Kim, C. H. (2021). Clinical usefulness of deep learning-based automated segmentation in intracranial hemorrhage. *Technology and Health Care* (s. 881-895). içinde
- Mayo. (2022). *Lung Cancer*.
- Mirza, S. &. (2017). Neuroimaging in Intracerebral Hemorrhage. *Hemorrhagic Stroke*.
- Patel, A. S. (2019). *Intracerebral Haemorrhage Segmentation in Non-Contrast CT*. Scientific Reports.
- Prevention, U. C. (2017). *CDC 2017: 'Screening for Lung Cancer – 10 States*.
- Qdaisat, A. Y. (2022). Characteristics and Outcomes of Intracranial Hemorrhage in Cancer Patients Visiting the Emergency Department. *Journal of Clinical Medicine*, 643.
- Siegel, R. L. (2021). Cancer Statistics. *CA: A Cancer Journal for Clinicians*.
- Society, A. C. (2019). *What is Lung Cancer*.
- Unnithan AKA, M. P. (2022). Hemorrhagic Stroke. *StatPearls [Internet]*.
- van Dam, M. A.-O.-F.-J. (2021). Overview and Future Perspectives on Tumor-Targeted Positron Emission Tomography and Fluorescence Imaging of Pancreatic Cancer in the Era of Neoadjuvant Therapy. *Cancers*.
- Ye, H. G. (2019). Precise diagnosis of intracranial hemorrhage and subtypes using a three-dimensional joint convolutional and recurrent neural network. *European Radiology*, 6191-6201.
- Yousufuddin, M. M. (2020). Initial and subsequent 3-year cost after hospitalization for first acute ischemic stroke and intracerebral hemorrhage. *ournal of the Neurological Sciences*.